

Genetic Testing for Developmental Delay: Keep Searching for an Answer

David T. Miller,^{1,2,4*} Yiping Shen,^{1,4} David J. Harris,^{2,4} Bai-Lin Wu,^{1,4} and Magdi M. Sobeih^{3,4}

¹Department of Laboratory Medicine, ²Division of Genetics, and ³Neurolinguistics Clinic/Behavioral Neurology in Department of Neurology, Children's Hospital Boston, Boston, MA; ⁴Harvard Medical School, Boston, MA.

*Address correspondence to this author at: Department of Laboratory Medicine, Children's Hospital Boston, 300 Longwood Ave., Boston, MA 02115. Fax: 617-730-0338; e-mail david.miller2@childrens.harvard.edu.

CASE

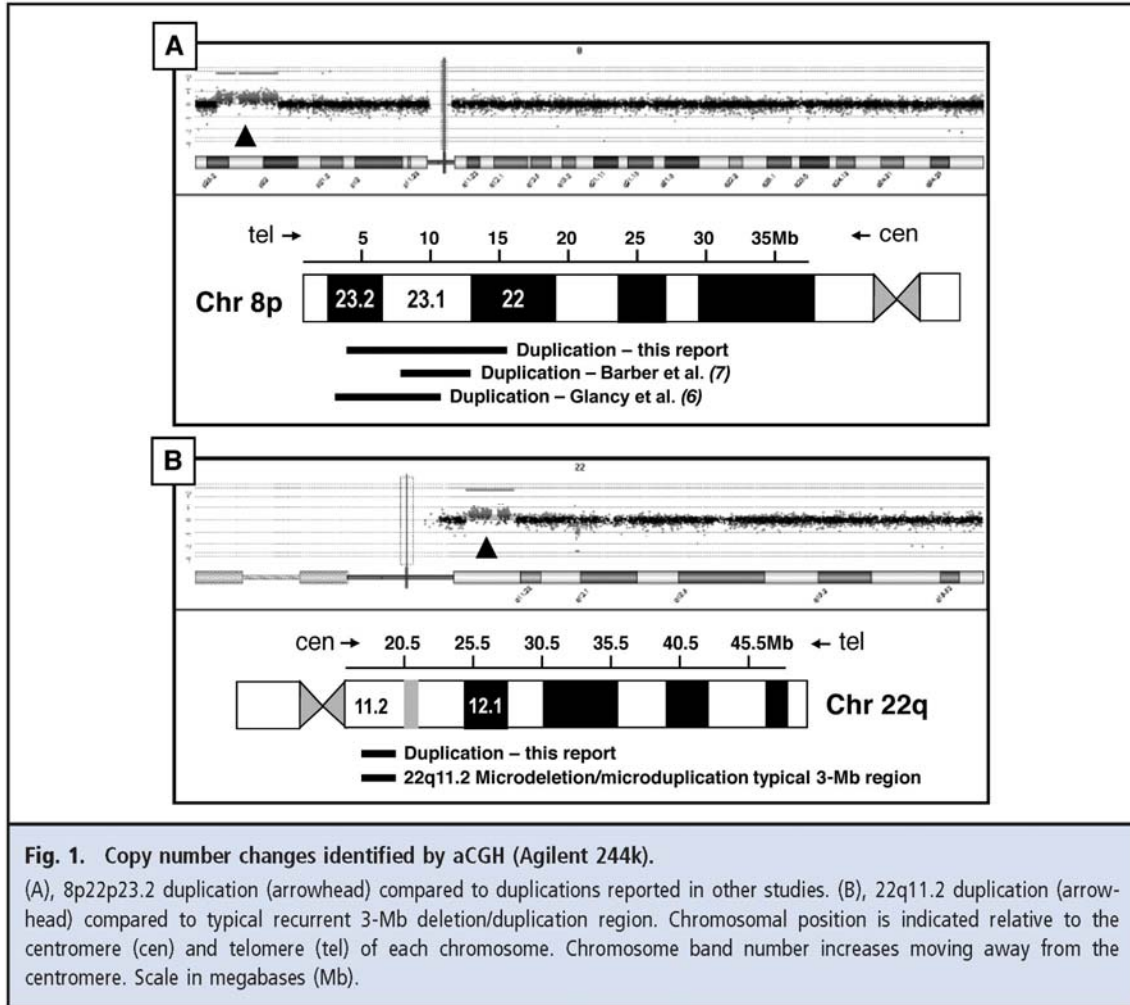
A 6-year-old girl of Irish, English, and French ancestry was referred to a pediatric neurologist for evaluation of developmental delay. She presented with expressive language delay with disarticulation. She did not speak in phrases until age 3, and formal testing revealed a language equivalent of 3 years 4 months when she was 5 years 6 months old (Clinical Evaluation of Language Fundamentals–Preschool) and an IQ of 64 (Wechsler Preschool & Primary Scale of Intelligence). Gross motor development was also delayed; she first walked at age 17–18 months. She never had any developmental regression. There was a family history of learning disability in her mother and a maternal uncle, and a maternal first cousin once removed was born with myelomeningocele.

She was delivered at term after an uncomplicated pregnancy that was conceived by in vitro fertilization. At 10 days of age, she was diagnosed with atrioventricular (A-V) canal malformation and coarctation of the aorta. She underwent surgical repair of her coarctation at age 10 days and of her A-V canal defect at age 4 months. She had a bifid uvula, a finding often associated with presence of a submucous cleft palate. Modified barium swallow demonstrated a poorly coordinated swallow reflex leading to poor feeding and aspiration. As an infant, she had true vocal cord paralysis, believed to be a complication from intubation. She had gastroesophageal reflux disease, treated with ranitidine (Zantac), and was diagnosed with mild vesicoureteral reflux after a urinary tract infection at age 7 months. She has not had any episodes suggesting seizures or any features of autism other than language delay.

Notable physical exam features include widely spaced eyes (hypertelorism), bulbous nasal tip, high arched palate, and fifth finger clinodactyly. Her neurologist ordered an MRI that showed mild thinning of the corpus callosum with prominence of the lateral and third ventricles, all nonspecific findings. Multiple genetic tests were ordered during infancy to determine the cause of her cardiac anomalies and developmental delays. The history of A-V canal malformation and aortic coarctation raised suspicion for microdeletion of chromosome 22q11.2, also called velocardiofacial syndrome. Fluorescence in situ hybridization (FISH) for chromosome 22q11.2 was normal. G-banded karyotype, *PTPN11* gene sequencing for Noonan syndrome, and fragile X DNA testing results were also normal.

At age 3 years, array comparative genomic hybridization (aCGH) was ordered from an outside laboratory. This whole-genome array of 2600 bacterial artificial chromosome (BAC) clones (Spectral Genomics, Inc.) spaced 1Mb apart showed a gain in copy number of BAC clones extending from clone RP11–1K11 at 8p23.2 (chr8: 4 596 114–4 755 793; human genome build 18) to clone RP11–23H1 at 8p22 (chr8: 15 027 287–15 191 603; hg18) indicative of an approximately 10.6-Mb duplication at 8p22p23.2. Neither parent was a carrier of the 8p22p23.2 duplication based on FISH testing, indicating a de novo copy number change.

Two years later, the patient's neurologist ordered high-resolution whole genome oligonucleotide microarray (244K array G4411B; Agilent Technologies), taking advantage of this new technology to gather more information. This test again identified the 8p22p23.2 duplication, and defined the lesion more precisely as an 11.5-Mb duplication (chr8: 3 969 033–15 475 755; hg18). In addition, a 3.0-Mb duplication was identified at chromosome 22q11.2 (chr22: 17 086 001–20 131 661; hg18) (Fig. 1).



Questions to Consider
<ul style="list-style-type: none"> • Why are genomic copy number changes such a common cause of developmental delay/mental retardation?
<ul style="list-style-type: none"> • What accounts for the variable penetrance and expressivity of symptoms among individuals with 22q11.2 deletions and duplications?
<ul style="list-style-type: none"> • How will this diagnosis impact the family in terms of reproductive decision-making, and how does this type of genetic testing impact families in general?

Final Publication and Comments

The final published version with discussion and comments from the experts will appear in the April 2009 issue of *Clinical Chemistry*. To view the case and comments online, go to <http://www.clinchem.org/content/vol55/issue4> and follow the link to the Clinical Case Study and Commentaries.

Educational Centers

If you are associated with an educational center and would like to receive the cases and questions 2-3 weeks in advance of publication, please email clinchem@aacc.org.

AACC is pleased to allow free reproduction and distribution of this Clinical Case Study for personal or classroom discussion use. When photocopying, please make sure the DOI and copyright notice appear on each copy.

All previous Clinical Cases Studies can be accessed and downloaded online at <http://www.aacc.org/resourcecenters/casestudies/>.

AACC is a leading professional society dedicated to improving healthcare through laboratory medicine. Its nearly 10,000 members are clinical laboratory professionals, physicians, research scientists, and others involved in developing tests and directing laboratory operations. AACC brings this community together with programs that advance knowledge, expertise, and innovation. AACC is best known for the respected scientific journal, *Clinical Chemistry*, the award-winning patient-centered web site *Lab Tests Online*, and the world's largest conference on laboratory medicine and technology. Through these and other programs, AACC advances laboratory medicine and the quality of patient care.